Newborn life support

FOLLOWING INITIAL ASSESSMENT AND INTERVENTION, CONTINUE RESPIRATORY SUPPORT IF:

THE INFANT HAS NOT ESTABLISHED ADEQUATE, REGULAR BREATHING, OR

THE HEART RATE IS <100 MIN..

ENSURING AN OPEN AIRWAY, AERATING AND VENTILATING THE LUNGS IS USUALLY ALL THAT IS NECESSARY. WITHOUT THESE, OTHER INTERVENTIONS WILL BE UNSUCCESSFUL

Airway

Commence life support if initial assessment shows that the infant has ▶
not established adequate regular normal breathing, or has a heart rate ▶
<100 min (Fig. 5). ▶
Establishing and maintaining an open airway is essential to ▶
achieve postnatal transition and spontaneous breathing, or for further ▶
resuscitative actions to be effective ▶

Techniques to help open the airway

- Place the infant on their back with the head supported in a neutral position (Fig.6).
- Head in a neutral position. Face is horizontal (middle picture), neither flexed (left) or extended (right).

In floppy infants, pulling the jaw forwards (jaw lift) may be essential in opening and/or maintaining the airway and reducing mask leak (Fig6). When using a facemask, two person methods of airway support are superior and permit true jaw thrust to be applied.

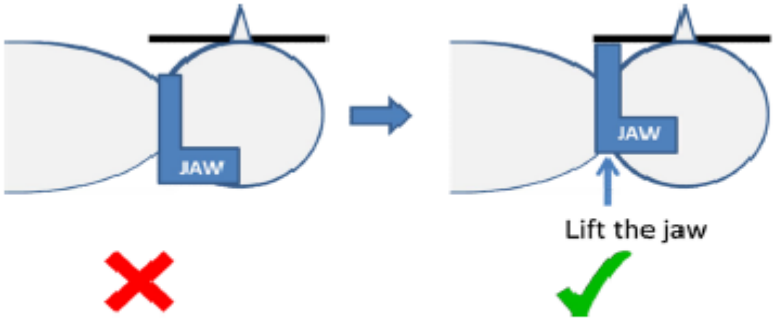

Fig. 6b – Jaw lift – jaw lift enlarges the pharyngeal spa

An oropharyngeal airway may be useful in term infants when having difficulty providing both jaw lift and ventilation, or where the upper airway is obstructed, for instance in those with micrognathia. However, oropharyngeal airways should be used with caution in infants 34 weeks gestation as they may increase airway obstruction.

A nasopharyngeal airway may also be considered where there is difficulty maintaining an airway and mask support fails to achieve adequate aeration

Airway obstruction

Airway obstruction can be due to inappropriate positioning, decreased airway tone and/or laryngeal adduction, especially in preterm infants at birth.

Suction is only required if airway obstruction due to mucus, vernix, meconium, blood clots, etc. is confirmed through inspection of the pharynx after failure to achieve aeration.

Any suctioning should be undertaken under direct vision, ideally using a laryngoscope and a wide bore catheter

Meconium

Non-vigorous newborn infants delivered through meconiumstained amniotic fluid are at significant risk for requiring advanced resuscitation and a neonatal team competent in advanced resuscitation may be required.

Routine suctioning of the airway of non-vigorous infants is likely to delay initiating ventilation and is not recommended. In the absence of evidence of benefit for suctioning, the emphasis

must be on initiating ventilation as soon as possible in apnoeic or ▶
ineffectively breathing infants born through meconium-stained ▶
amniotic fluid. ▶
Should initial attempts at aeration and ventilation be unsuccessful ▶
then physical obstruction may be the cause. In this case inspection ▶
and suction under direct vision be considered. Rarely, an infant ▶
may require tracheal intubation and tracheal suctioning to relieve ▶
airway obstruction. ▶
Initial inflations and assisted ventilation ▶

Lung inflation

- If apnoeic, gasping or not breathing effectively, aim to start positive pressure ventilation as soon as possible □ ideally within 60 s of birth.
- Apply an appropriately fitting facemask connected to a means of providing positive pressure ventilation, ensuring a good seal between mask and face.
- Give five "inflations" maintaining the inflation pressure for up s. 3 □to 2
- Provide initial inflation pressures of 30 cm H2O for term infants commencing with air. Start with 25 cm H2O for preterm infants 32 weeks using 21□ 30% inspired oxygen (see 'air/ oxygen').

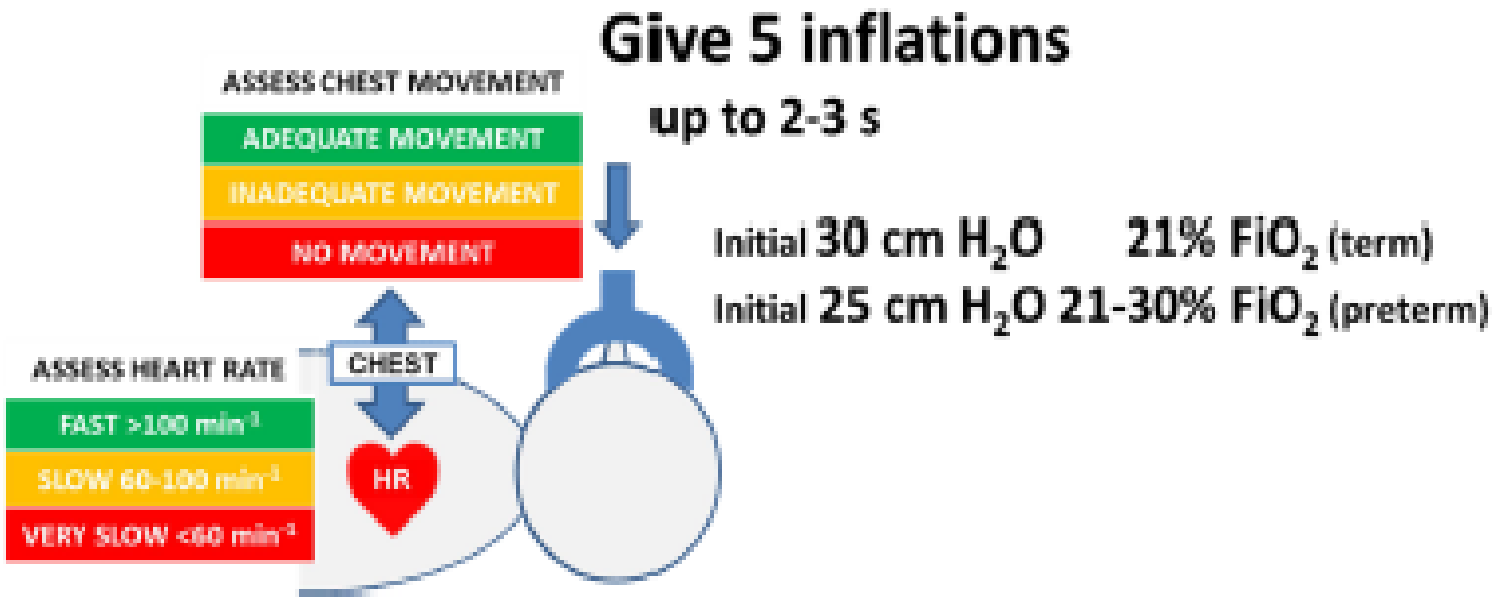

Fig. 7 – Five 2–3 s inflations are given via facemask. Assess heart rate response and chest movement.

Assessment

Check the heart rate

An increase (within 30 s) in heart rate, or a stable heart rate if initially high, confirms adequate ventilation/oxygenation.

A slow or very slow heart rate usually suggests continued hypoxia and almost always indicates inadequate ventilation.

Check for chest movement

Visible chest movement with inflations indicates a patent airway and delivered volume.

Failure of the chest to move may indicate obstruction of the airway, or insufficient inflation pressure and delivered volume to aerate the lungs.

Ventilation

If there is a heart rate response ▶

Continue uninterrupted ventilation until the infant begins to ▶

breathe adequately and the heart rate is above 100 min.. 1. ▶

Aim for about 30 breaths min.. 1 with an inflation time of under 1 s. ▶

Reduce the inflation pressure if the chest is moving well. ▶

Reassess heart rate and breathing at least every 30 s. ▶

Consider a more secure airway (laryngeal mask/tracheal tube) if ▶

apnoea continues or if mask ventilation is not effective ▶

Failure to respond

- If there is no heart rate response and the chest is not moving with inflations
- Check if the equipment is working properly.
- Recheck the head-position and jaw lift/thrust
- Recheck mask size, position and seal.

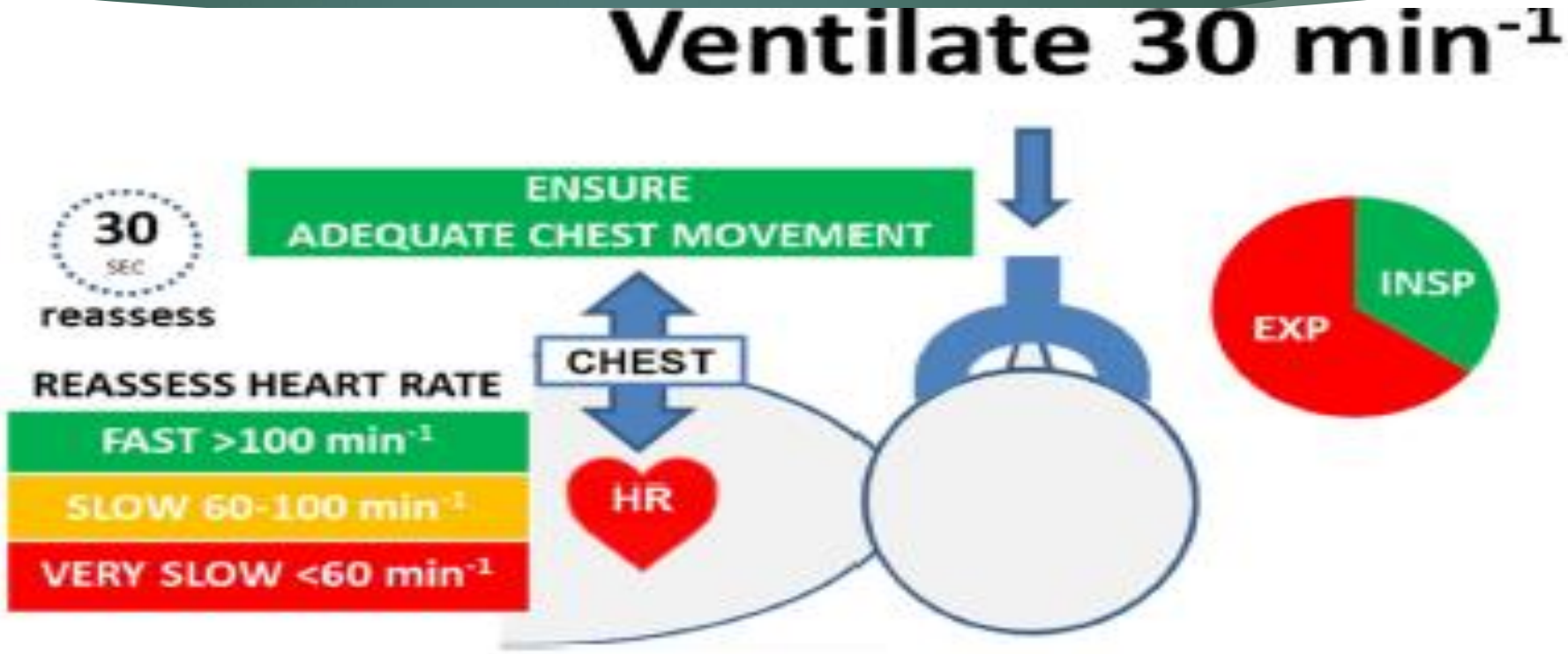

Fig. 8 – Once inflation breaths have been successfully delivered, ventilate at 30 breaths min^{-1}. Assess heart rate continuously.

- Consider other airway manoeuvres:
- 2-person mask support if single handed initially.
- Inspection of the pharynx and suction under direct vision to remove obstructing foreign matter if present.
- Securing the airway via tracheal intubation or insertion of a laryngeal mask.
- Insertion of an oropharyngeal/nasopharyngeal airway if unable to secure the airway with other means.
- Consider a gradual increase in inflation pressure.
- If being used, check on a respiratory function monitor that expired tidal volume is not too low or too high (target about 5□ 8mLkg

Then:

- Repeat inflations.
- Continuously assess heart rate and chest movement.
- If the insertion of a laryngeal mask or tracheal intubation is considered, it must be undertaken by personnel competent in the procedure with appropriate equipment. Otherwise continue with mask ventilation and call for help.

Without adequate lung aeration, chest compressions will be ▶
ineffective; therefore, where the heart rate remains very slow, confirm ▶
effective ventilation through observed chest movement or other ▶
measures of respiratory function before progressing to chest ▶
compressions. ▶

CPAP and PEEP/airway adjuncts and assisted ventilation ▶

Continuous positive airway pressure (CPAP) and positive end expiratory pressure (PEEP

- In spontaneously breathing preterm infants consider CPAP as the initial method of breathing support after delivery .. using either mask or nasal prongs.
- If equipment permits, apply PEEP at minimum of 5.. 6 cm H2O when providing positive pressure ventilation (PPV) to these infants.

Assisted ventilation devices

- Ensure a facemask of appropriate size is used to provide a good seal between mask and face
- Where possible use a T-piece resuscitator (TPR) capable of providing either CPAP or PPV with PEEP when providing ventilatory support, especially in the preterm infant.
- Nasal prongs of appropriate sizemay be a viableCPAPalternative to facemasks.
- Ifaself-inflatingbagisuseditshouldbeof sufficientvolumeto deliveran adequate inflation. Care should be taken not to deliver an excessive volume. The self-inflating bag cannot deliver CPAP effectively.

Laryngeal mask

Consider using a laryngeal mask

In infants of34 weeks gestation (about 2000 g) .. although some devices have been used successfully in infants down to 1500 g.

If there are problems with establishing effective ventilation with a facemask

Where intubation is not possible or deemed unsafe because of congenital abnormality, a lack of equipment, or a lack of skill.

Or as an alternative to tracheal intubation as a secondary airway.

Tracheal tube

Tracheal intubation may be considered at several points during neonatal resuscitation:

- When ventilation is ineffective after correction of mask technique and/or the infant's head position, and/or increasing inspiratory pressure with TPR or bag-mask.
- Where ventilation is prolonged, to enable a more secure airway to be established.
- When suctioning the lower airways to remove a presumed tracheal blockage.
- When chest compressions are performed.
- In special circumstances (e.g., congenital diaphragmatic hernia or to give surfactant).

- Exhaled CO_2 detection should be used when undertaking intubation to confirm tube placement in the airway.
- A range of differing sized tracheal tubes should be available to permit placement of the most appropriate size to ensure adequate ventilation with minimal leak and trauma to the airway (Table 1).
- Respiratory function monitoring may also help confirm tracheal tube position and adequate ventilation through demonstrating adequate expired tidal volume (about 5□ 8mLkg□ 1) and minimal leak.
- The use of a video laryngoscope may aid tube placement.
- If retained, the position of the tracheal tube should be confirmed by radiography.

Table 1 – Approximate oral tracheal tube size by gestation (for approximate nasotracheal tube length add 1 cm).

Gestational age (weeks)	Length at lips (cm)	External diameter (mm)
23–24	5.5	2.5
25–26	6.0	2.5
27–29	6.5	2.5
30–32	7.0	3.0
33–34	7.5	3.0
35–37	8.0	3.5
38–40	8.5	3.5
41–43	9.0	4.0

If, despite effective ventilation, there is no increase in heart rate, or ▶
saturations remain low, increase the oxygen concentration to ▶
achieve adequate preductal oxygen saturations. ▶
Check the delivered inspired oxygen concentration and saturations ▶
frequently (e.g. every 30 s) and titrate to avoid both hypoxia ▶
and hyperoxia. ▶
wean the inspired oxygen if saturations >95% in preterms ▶

Term and late preterm infants 35 weeks

- In infants receiving respiratory support at birth, begin with air (21%).

Preterm infants <35 weeks

Resuscitation should be initiated in air or a low inspired oxygen concentration based on gestational age:

[1293TD$DIF]32 weeks 21%

28.. 31 weeks 21.. 30%

<28 weeks 30%

In infants <32 weeks gestation the target should be to avoid an oxygen saturation below 80% and/or bradycardia at 5 min of age. Both are associated with poor outcome.

Thank you!